



**PATIENT**

Tank Pointer

**SPECIES**

Canine

**BREED**

Chihuahua Mix

**SEX**

Male Neutered

**AGE**

10 years

**WEIGHT**

18.5lbs

**INTERPRETED BY**

Maggie Machen Lamy, DVM DACVIM (Cardiology)

**IMAGING PERFORMED BY**

Pamela Harrigan, RDCS

**HOSPITAL NAME**

Mass Veterinary Services

**REFERRING VET**

Dr. Masloski

**INVOICE**

30420

**DATE**

4/25/23

**PRESENTING CLINICAL SIGNS**

History: Recheck echo. History chronic valvular disease (late B2). Presently, Tank has occasional heavy breathing. Snores when sleeping. Eating well with normal activity level. On exam: NSR, grade IV/VI murmur with PMI left apical area radiating to right, PSS, lung fields clear, mm pink, moist, CRT<2. BP: 150-160 mmHg. Current medications: 1) Glucosamine 2) Omega 3 fatty acids 3) Pimobendan/vetmedin7.5mg 1/3 tab twice a day 4) Spironolactone 25mg 1/2 tab twice a day \*No sedation for study.

-Pertinent previous echo findings: LA 3.0 cm; LA:A0 2.5; LV 3.6 cm; severe LAE, severe MR, mild-moderate TR (3.3 m/s; 45 mmHg)

**ECHOCARDIOGRAM FINDINGS**

2D, m-mode, color flow and Doppler imaging is available.

**Left ventricle:** The LV diameter is increased with hyperdynamic function. LV wall thicknesses are normal.

**Left atrium:** The left atrium is severely dilated.

**Mitral valve:** The mitral valve is diffusely thickened with prolapse into the left atrial lumen. Severe eccentric mitral regurgitation with a normal velocity.

**Aortic valve/Aorta:** The aortic valve appears thickened with borderline increased outflow velocity; laminar flow. Trace aortic insufficiency.

**Right ventricle:** Mild right ventricular enlargement.

**Right atrium:** Mild RA enlargement.

**Tricuspid valve:** The tricuspid valve appears mildly thickened with mild to moderate tricuspid regurgitation. Velocity consistent with mild to moderate pulmonary hypertension.

**Pulmonic valve/Pulmonary artery:** The pulmonic valve is normal in morphology and mobility. No pulmonic insufficiency. Normal RVOT velocity; laminar flow.

**Pericardium/other:** No pericardial or pleural effusion noted. No obvious cardiac masses.

**Heart rhythm:** ECG reveals a sinus rhythm with an average HR of 150bpm.

**2-Dimensional Measurements**

|                    |     |
|--------------------|-----|
| Ao diam (cm)       | 1.4 |
| LA diam (cm)       | 3.3 |
| LA:Ao (Swe)        | 2.4 |
| IVS thickness (cm) | 0.8 |
| LVID diastole (cm) | 4.1 |
| PW thickness (cm)  | 0.8 |
| LVID systole (cm)  | 1.9 |
| FS (%)             | 54  |

**Doppler Measurements**

|                |      |
|----------------|------|
| PV Vmax (m/s)  | 0.93 |
| AoV Vmax (m/s) | 1.7  |
| MR Vmax (m/s)  | 5.4  |
| TR Vmax (m/s)  | 3.4  |
| TR PG (mmHg)   | 48   |

**INTERPRETATION OF THE FINDINGS**

Chronic degenerative valve disease persists with findings similar to the previous report. Severe mitral and mild to moderate tricuspid regurgitation are unchanged. The left and right heart dimensions are similar to what is described previously with stable pulmonary pressures. A small aortic insufficiency is noted, and lifelong blood pressure monitoring is advised. No additional concurrent issues are documented.

Given these findings, continue Pimobendan and Spironolactone as previously recommended. An ACE-I should also be considered. Assessment of progression in the future will help predict long term outcome, however prognosis is guarded at this stage (late B2). Unfortunately, the patient will always be at risk for recurrent CHF, development of arrhythmias/LA tear, syncope and/or sudden death in the future.



**PATIENT**

Tank Pointer

**SPECIES**

Canine

**BREED**

Chihuahua Mix

**SEX**

Male Neutered

**AGE**

10 years

**WEIGHT**

18.5lbs

**INTERPRETED BY**

Maggie Machen Lamy, DVM  
DACVIM (Cardiology)

**IMAGING PERFORMED BY**

Pamela Harrigan, RDCS

**HOSPITAL NAME**

Mass Veterinary Services

**REFERRING VET**

Dr. Masloski

**INVOICE**

30420

**DATE**

4/25/23

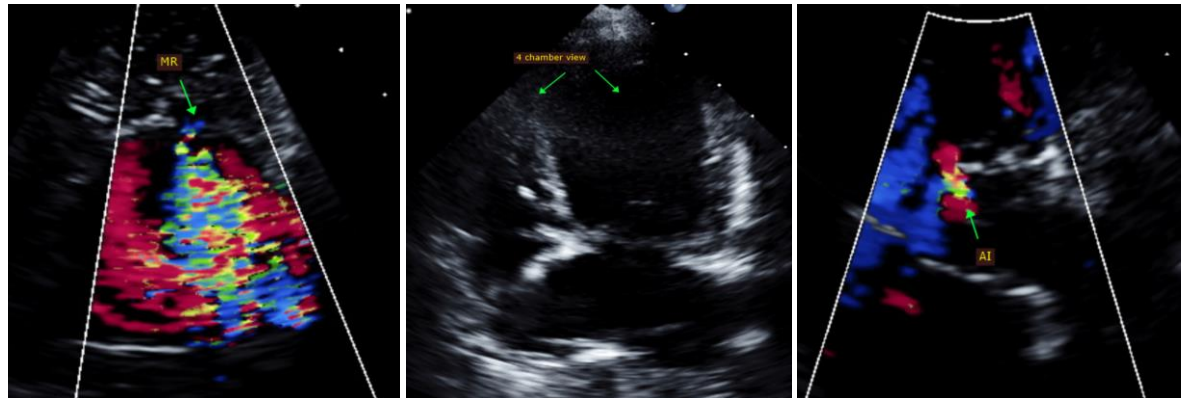
**RECOMMENDATIONS**

- Continue Pimobendan 0.3mg/kg PO q12h.
- Institute ACE-I (benazepril or enalapril) 0.5mg/kg PO q12h.
- Continue spironolactone 1-2mg/kg PO q12h.
- Close monitoring for development of associated clinical signs (development of a cough, labored breathing, exercise intolerance or worsening collapse episodes) is recommended. Monitoring of sleeping breathing rates is recommended as the best way to screen for CHF at home.
- Omega fatty acid supplementation and mild salt restriction may be of some long-term benefit. Mild activity restriction is advised.
- Elective anesthesia is not advised, as there is high risk for complication. If necessary, cardiac protective drug choices (opioid/benzodiazepine premedication, propofol or alfaxalone induction, iso or sevoflurane gas) are recommended. Pre-oxygenate for 5-10 minutes prior to induction and recover in O2 cage. Monitor for arrhythmias, hypotension, and hypoxia both intra and post-operatively and intervene as necessary. Moderate IV fluid restriction is recommended to avoid fluid overload. Avoid heart rate stimulating drugs such as atropine unless clinically indicated.

**PLAN**

- A renal panel is recommended every 3-4 months lifelong.
- Recommend conservative monitoring with a recheck echocardiogram in 6 months, sooner if any development of clinical signs.

**IMAGES**



The information and recommendations provided are based on the images presented by the referring veterinarian. No evaluation can be communicated regarding pathology that was not visible in the image/video clips provided.

Thank you for this referral. This report was generated using transcription software, and minor dictation errors may be present. If the clinical or image interpretation does not parallel your findings or if I can be of any further assistance, please contact me.

Maggie Machen Lamy, DVM  
Diplomate of the American College of Veterinary Internal Medicine (Cardiology)  
info@sonopath.com

Echocardiogram performed by: Pamela Harrigan, RDCS  
Pet Animal Ultrasound Service (4paus.com)